

## Why do we need your help?

- Greater awareness and education is needed to improve familiarity of intracranial hypotension and spinal CSF leak among health care professionals and the general public. This will help to shorten delays to diagnosis and treatment.
- The full range of specialized diagnostic imaging is not available in all centers and even in expert hands may still fail to identify a leak.
- While a good prognosis is possible, many patients suffer for years despite currently available treatments.
- More research is needed to advance our understanding of all aspects of the disorder and to improve testing and treatments.

## Who we are

Spinal CSF Leak Foundation is a 501(c)(3) non-profit health advocacy organization.

Our mission is to reduce the suffering of persons affected by intracranial hypotension or spinal CSF leak.



because your dura maters®

100 N Howard St, Ste 5792  
Spokane WA 99201

[spinalcsfleak.org](http://spinalcsfleak.org)

## How can you help?

### get involved

[spinalcsfleak.org/get-involved](http://spinalcsfleak.org/get-involved)

### volunteer

[volunteer@spinalcsfleak.org](mailto:volunteer@spinalcsfleak.org)

### donate

[spinalcsfleak.org/donate](http://spinalcsfleak.org/donate)

### fundraise

[spinalcsfleak.org/get-involved/fundraise](http://spinalcsfleak.org/get-involved/fundraise)

### follow us online

-  [twitter.com/spinalCSFleak](https://twitter.com/spinalCSFleak)
-  [facebook.com/Spinal.CSf.Leak.Foundation](https://facebook.com/Spinal.CSf.Leak.Foundation)
-  [instagram.com/spinalcsfleakusa](https://instagram.com/spinalcsfleakusa)
-  [youtube.com/c/SpinalCSFLeakFoundation](https://youtube.com/c/SpinalCSFLeakFoundation)



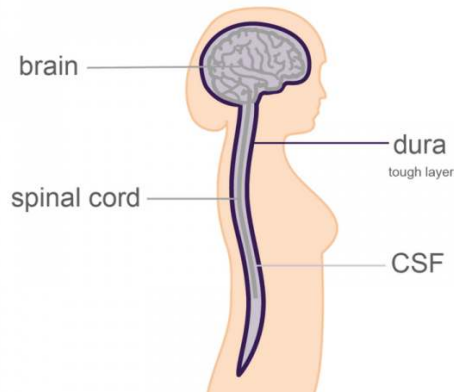
A Patient's Guide to

# Spinal CSF Leak



because your dura maters®

# What causes spinal csf leak?



## medical procedures (iatrogenic causes)

- lumbar puncture (spinal tap)
- epidural injection (spinal injection)
- spinal or other surgery

## injuries or trauma to the spine

- fall
- motor vehicle accident

## spontaneous

There are several types of spontaneous spinal CSF leaks:

- dural tears can be caused by spinal bone spur or calcified disc;
- a ruptured meningeal diverticula;
- An underlying weakness of the dura mater, often associated with a number of genetic connective tissue disorders, such as Marfan syndrome or Ehlers-Danlos syndrome; or
- CSF-venous fistula is an abnormal connection between the normal CSF space and veins outside the dura mater. Why these develop is not yet fully understood.

# What is a spinal csf leak?

**Spinal cerebrospinal fluid (CSF) leak is an important and under-diagnosed disorder that can happen to anyone.** Cerebrospinal fluid (CSF) bathes and supports the brain and spinal cord. This fluid is held inside layers of connective tissue called the meninges, which surround the brain and spinal cord. There are three meningeal layers: the pia mater; the arachnoid mater; and the dura mater. The dura mater, sometimes called the dura, is the outermost layer of the meninges. **A spinal CSF leak happens when the spinal dura mater has a hole or tear**, allowing cerebrospinal fluid to leak out of this enclosed space. This results in **intracranial hypotension**, a low volume of CSF remaining around the brain and spinal cord.

The most common symptom of a spinal CSF leak is positional head pain that is worse after minutes to hours upright and improved when lying down—but there are many other neurologic signs and symptoms. Head pain severity varies enormously and may not correlate well with findings on imaging. **Patients may be quite disabled** by their inability to be functional while upright. Recognition of the head pain pattern and other symptoms is important in leading physicians to suspect the diagnosis of intracranial hypotension.

## How is it diagnosed?

### symptoms

The diagnosis is suspected on the basis of the patient's symptoms.

### brain imaging

MRI of the head without and with contrast should be performed in most cases. There are several typical findings seen in about 80% of cases although normal imaging does not rule out the diagnosis.

### spinal imaging

Specialized spinal imaging is used to locate the CSF leak. MRI, CT, and digital subtraction imaging are used.

## How is it treated?

### initial treatment

Bedrest, fluids, and extra caffeine may allow some cases to resolve without any further treatment.

### spinal injection procedures

For those that require treatment, a type of spinal injection procedure called epidural blood patching is commonly performed. This can be repeated a number of times with blood alone or with blood and/or fibrin glue.

### surgery

Some patients require surgical repair by a neurosurgeon. A few patients will require a number of procedures.