



Photon counting CT myelography: what is it and how does it help?

Ajay Madhavan, M.D.

No disclosures / off label uses

Thanks to...

- **Mayo CT Clinical Innovation Center**

- Cynthia McCollough, PhD
- JG Fletcher, MD
- Francis Baffour, MD
- Nikki Weber, RT
- Lifeng Yu, PhD
- Shuai Leng, PhD

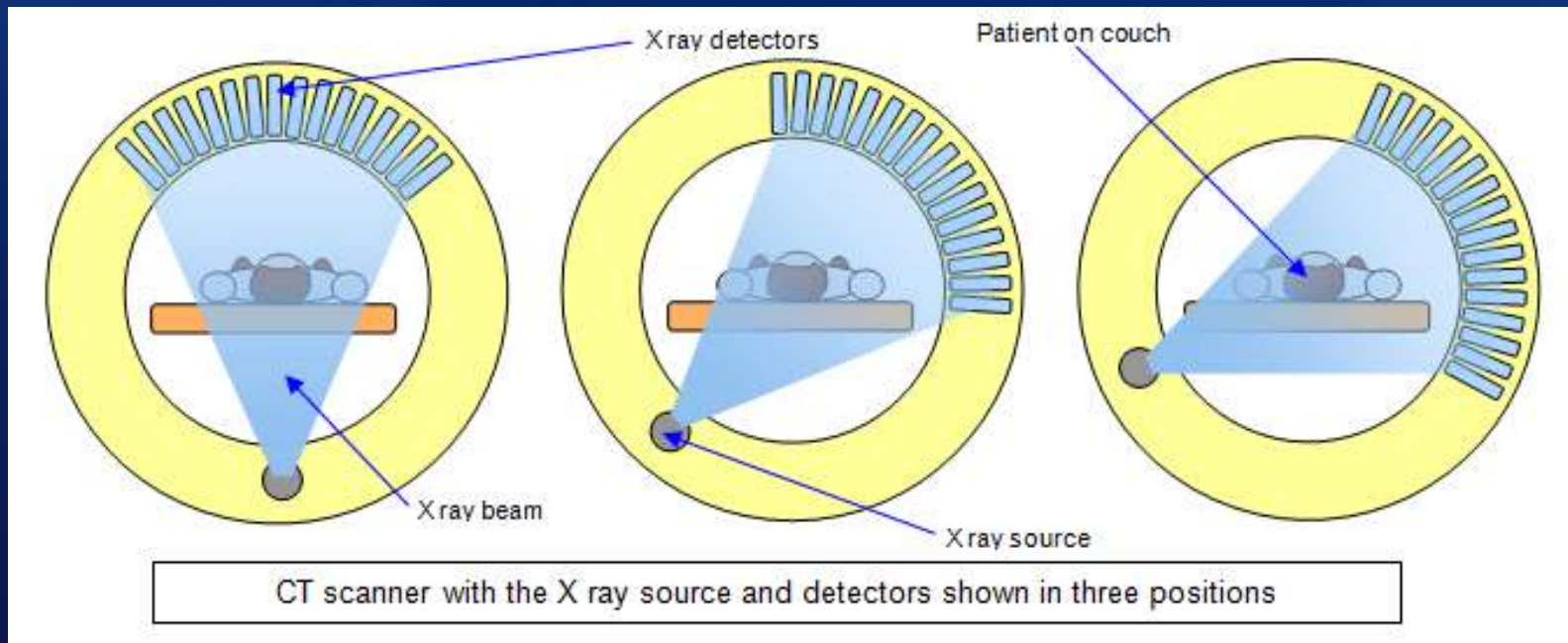
- **Colleagues / Mentors**

- Tim Amrhein, MD
- Peter Kranz, MD

Outline

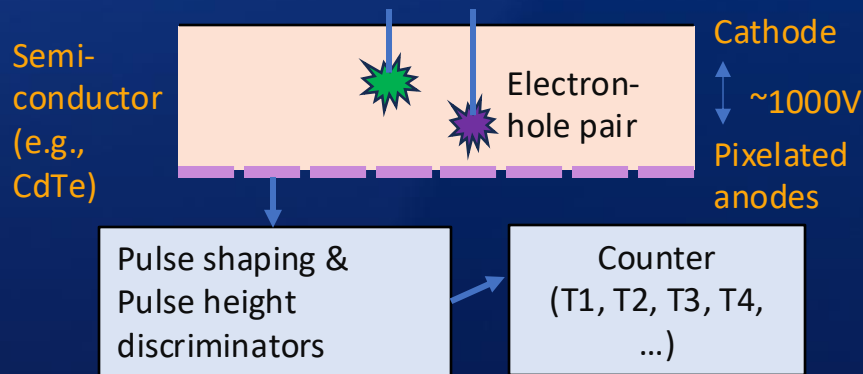
- What is photon counting detector CT (PCD-CT)?
- How can PCD-CT help patients with CSF leaks?
- Challenges and opportunities for improvement

How does a CT scanner work?



What's better about photon counting detector CT?

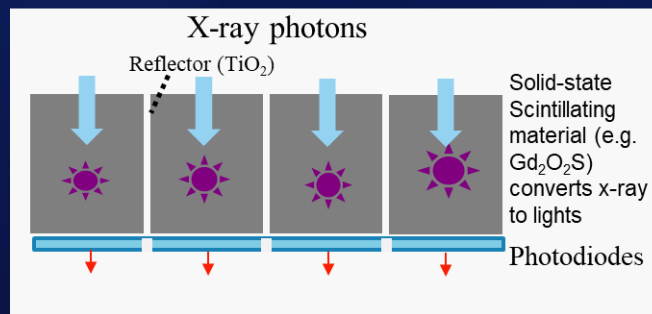
Photon-counting-detector CT (PCD-CT)



Advantages of PCD-CT over EID-CT

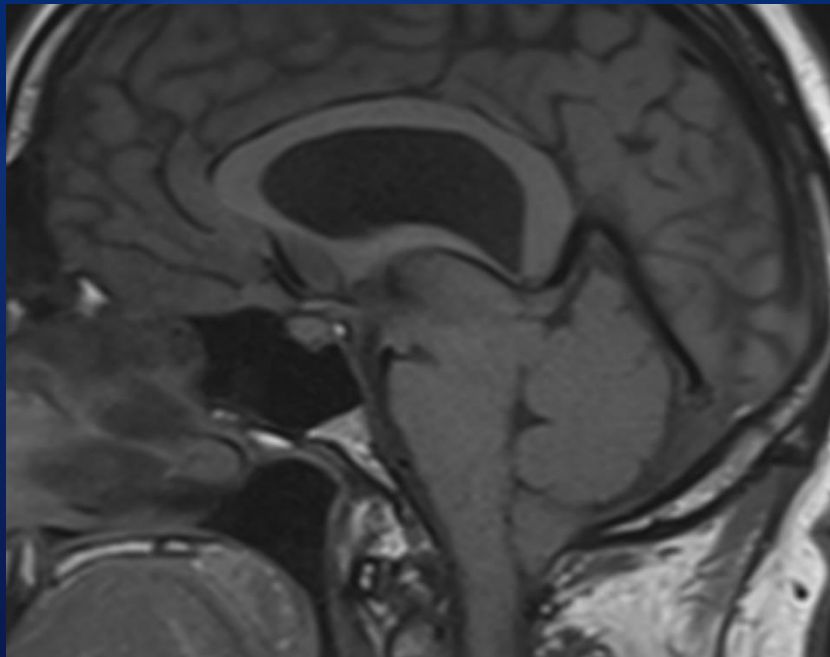
- Better spatial resolution
- Improve signal to noise ratio
- Inherent multi-energy spectral imaging
- Faster scan speeds

Energy-integrating-detector CT (EID-CT)

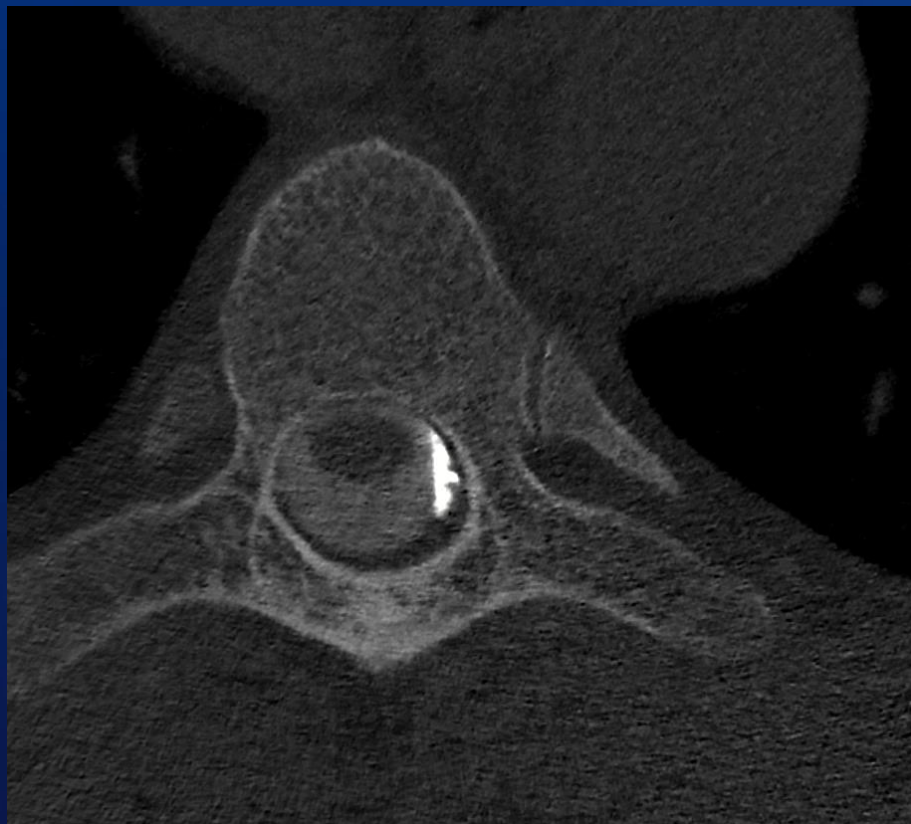

Why is PCD-CT potentially better?

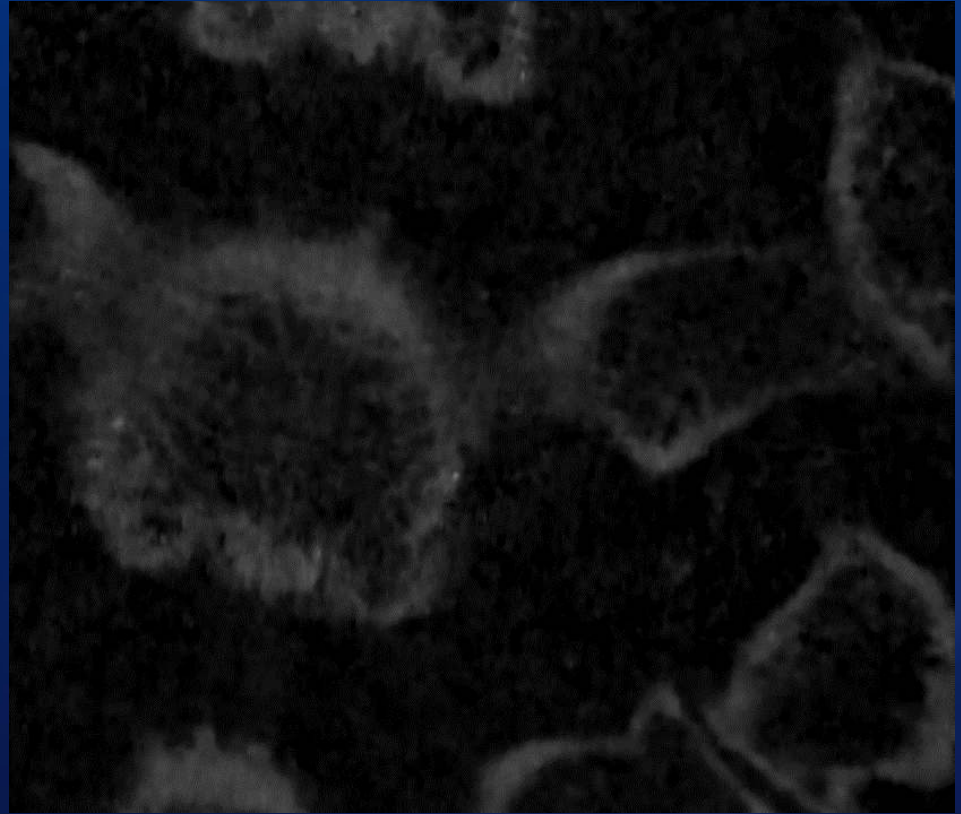
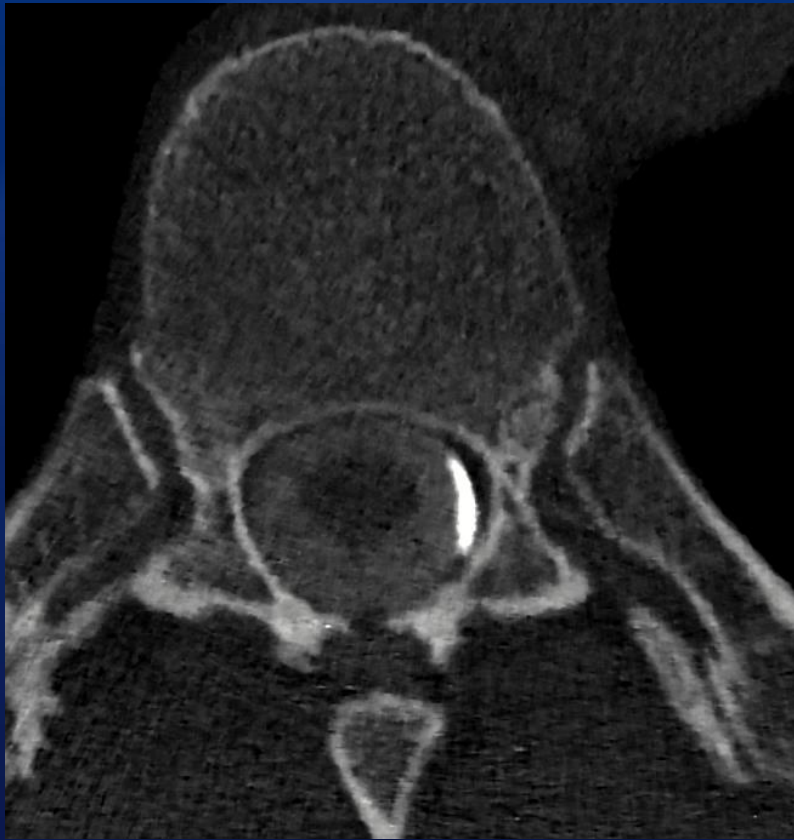- **Better spatial resolution**
 - Ultra-high resolution mode → 0.2 mm slices
- **Better temporal resolution**
 - Scans entire spine in 5-12 seconds
 - Minimal delay between scans (2 seconds)
- **Spectral imaging**
 - Ability to make contrast brighter
 - Helps to see subtle leaks



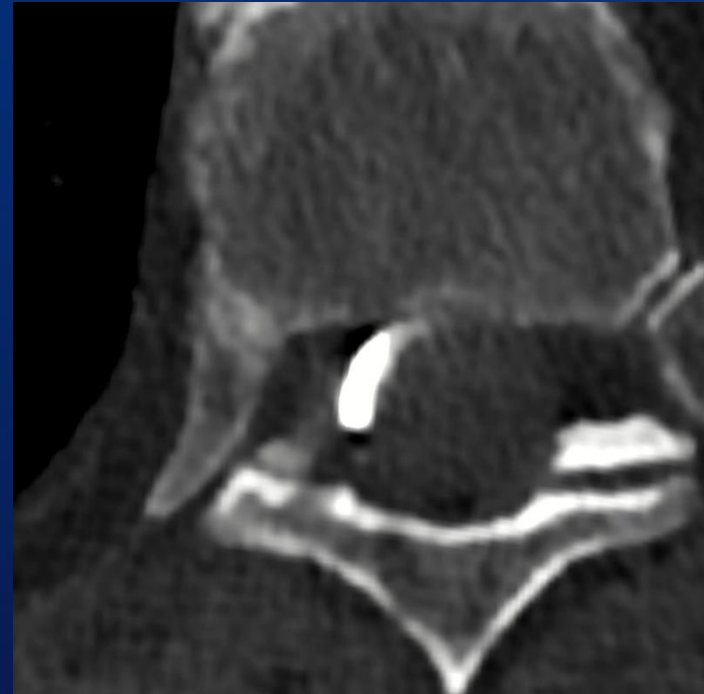
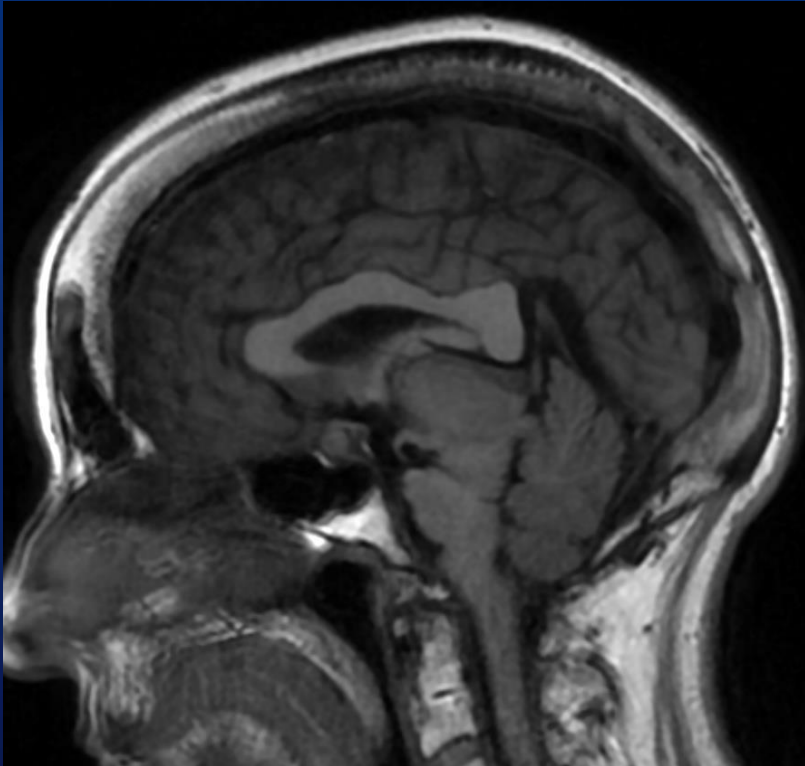
47yo M, 8 years of debilitating headaches, negative work-up elsewhere



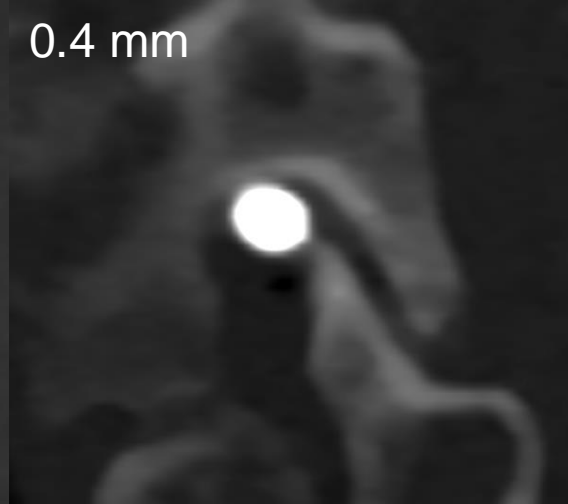
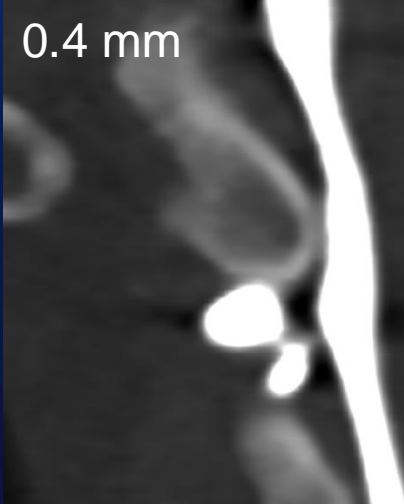
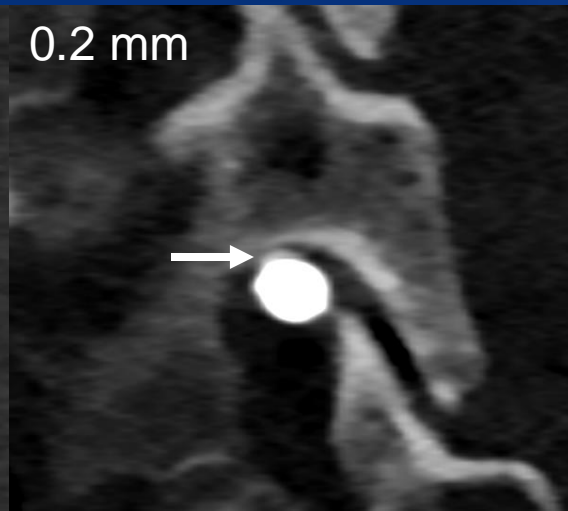
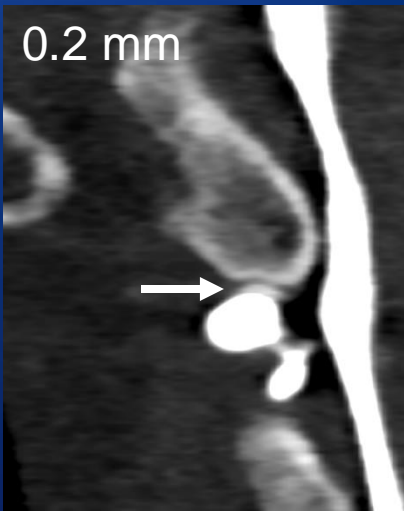Symptoms resolved within 2 days of treatment of this fistula



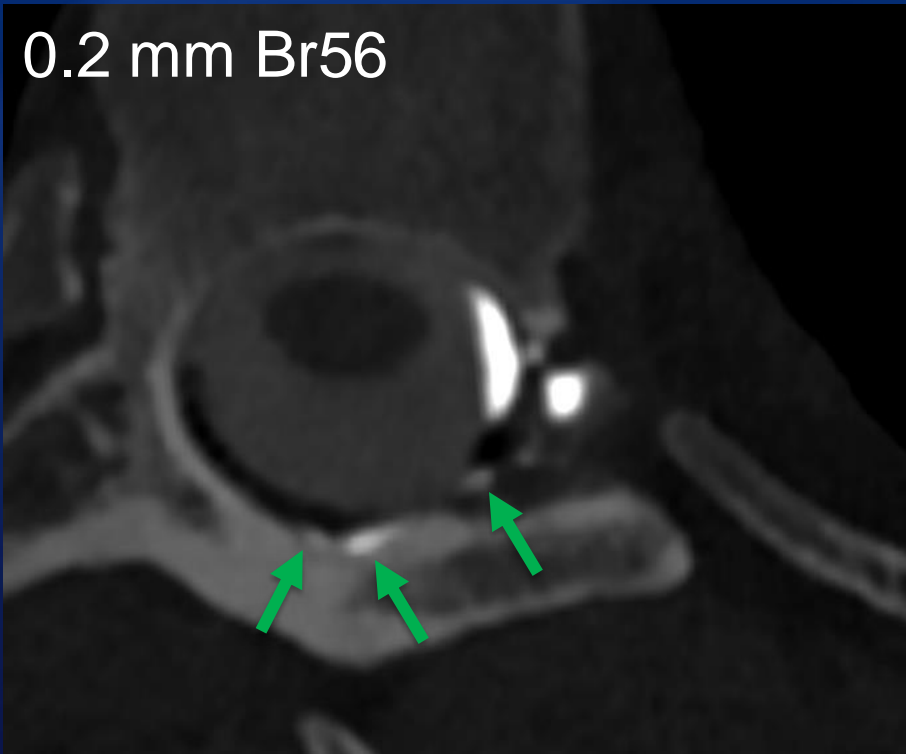
PCD-CTM: CSF-venous fistula



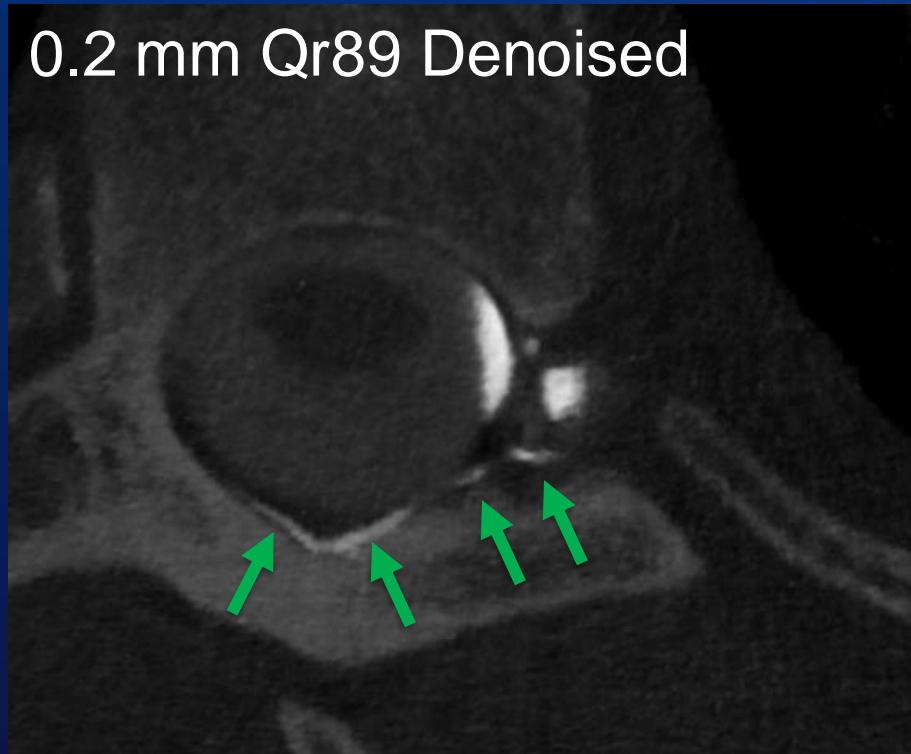
PCD CTM: Subtle CSF-venous fistula



0.2 mm Br56

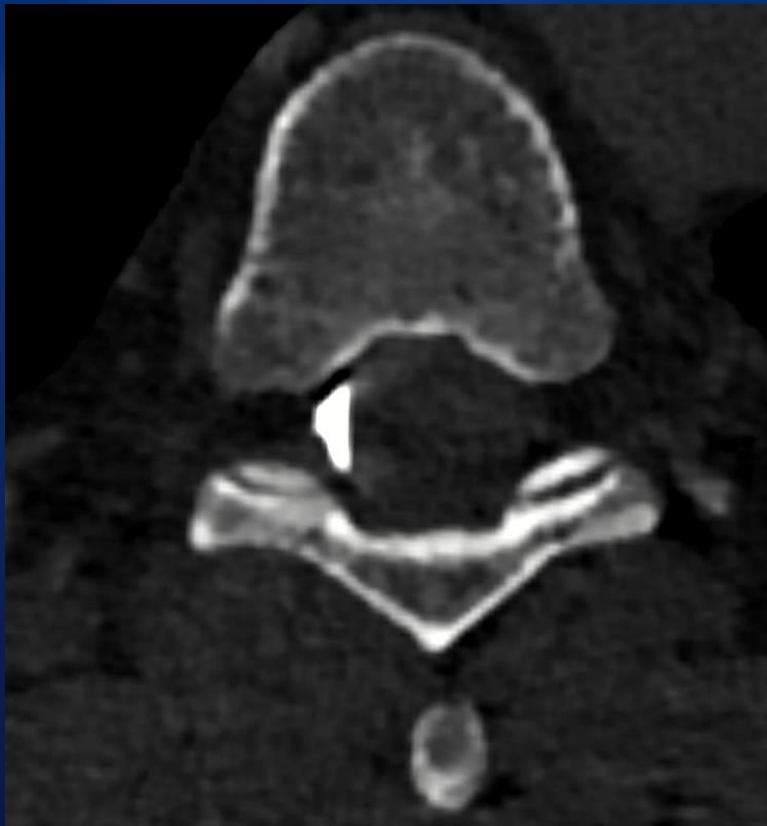


0.2 mm Qr89 Denoised

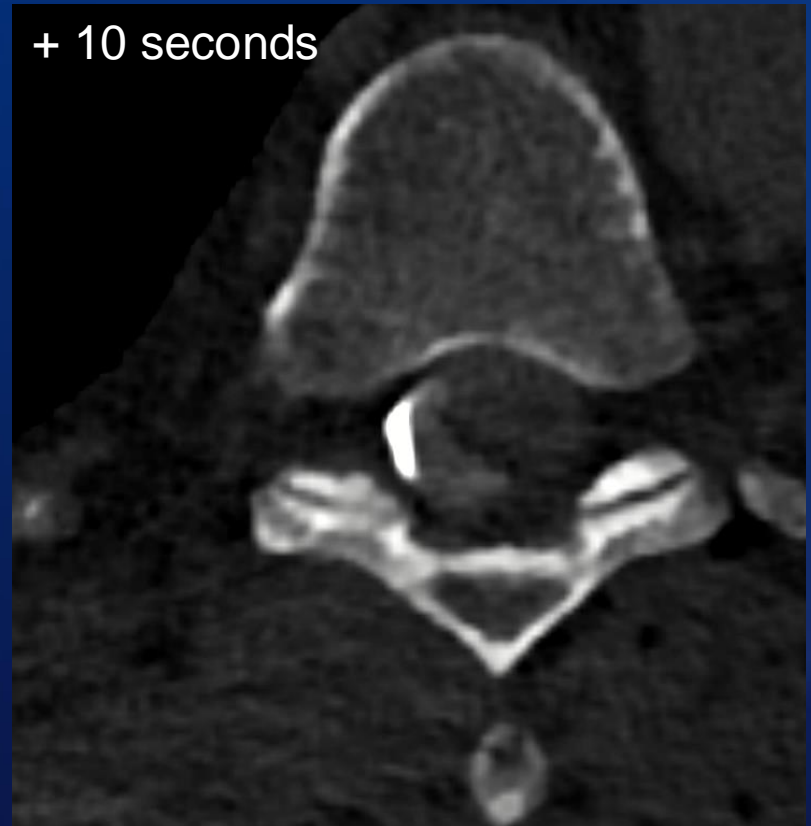

Why is PCD-CT potentially better?

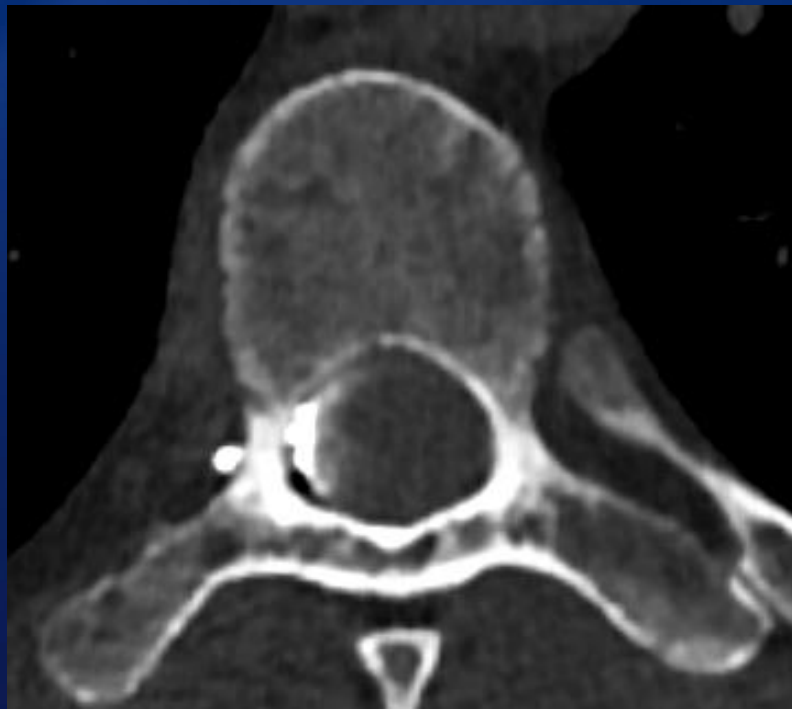
- **Better spatial resolution**
 - Ultra-high resolution mode → 0.2 mm slices
- **Better temporal resolution**
 - Scans entire spine in 5-12 seconds
 - Minimal delay between scans (2 seconds)
- **Spectral imaging**
 - Ability to make contrast brighter
 - Helps to see subtle leaks



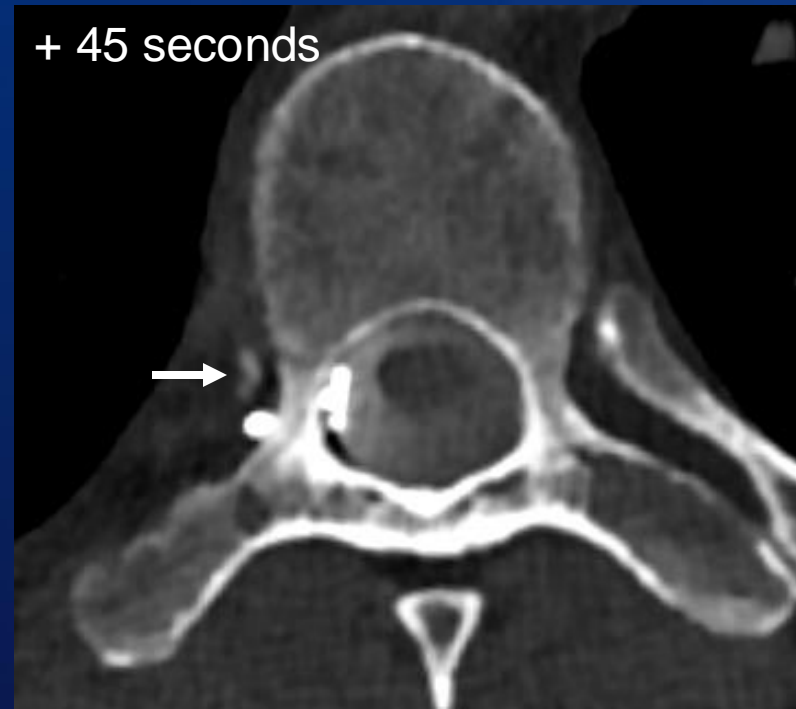
PCCT 0.2 mm



PCCT 0.2 mm



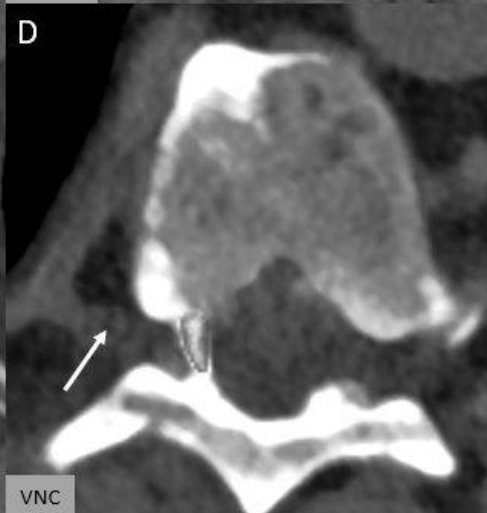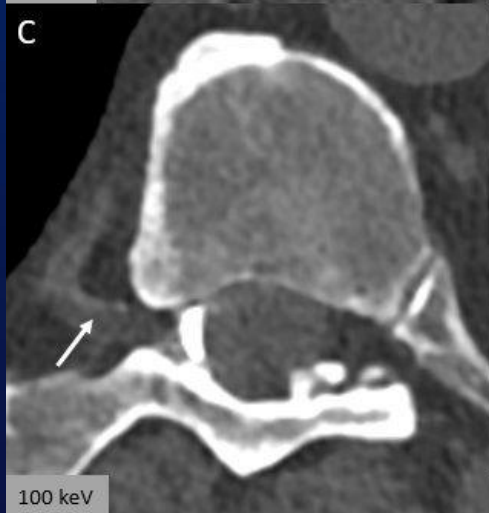
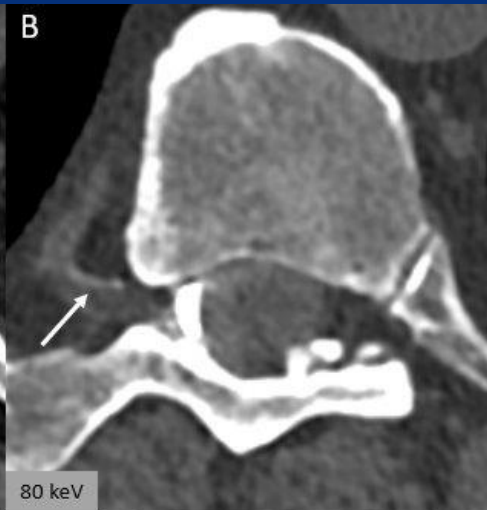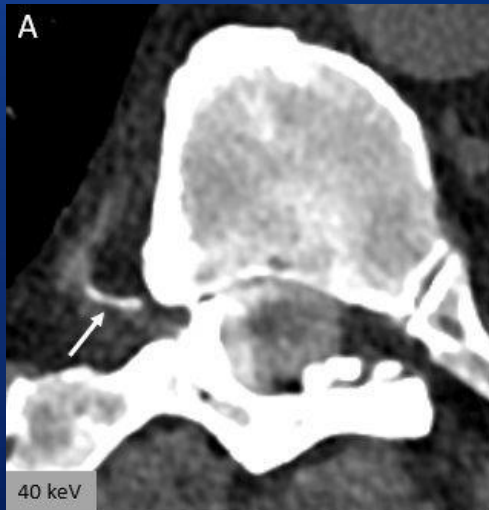
1st

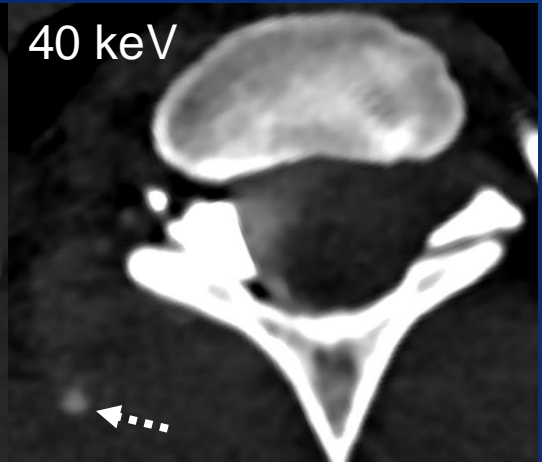
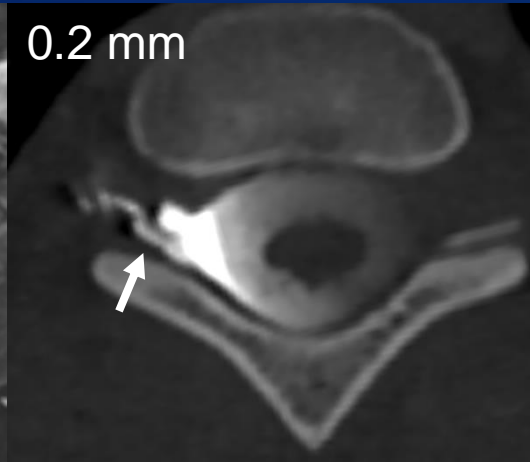
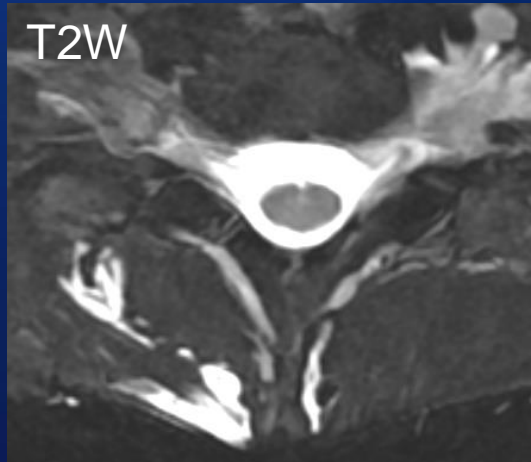


4th

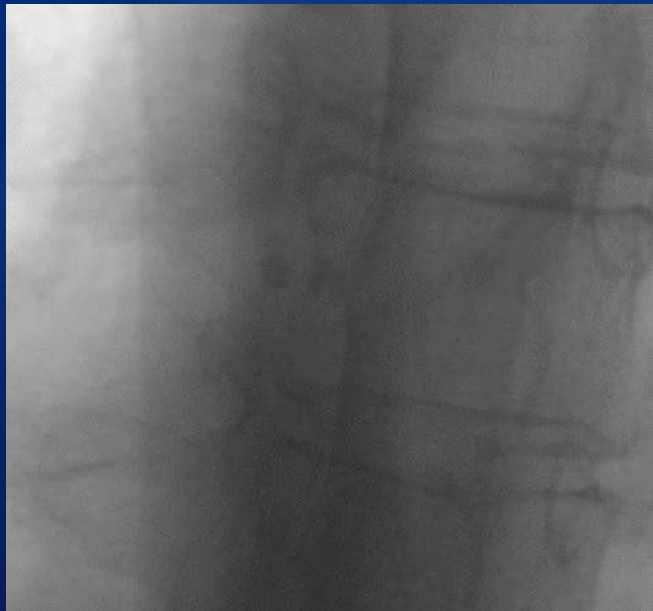Why is PCD-CT potentially better?

- **Better spatial resolution**
 - Ultra-high resolution mode → 0.2 mm slices
- **Better temporal resolution**
 - Scans entire spine in 5-12 seconds
 - Minimal delay between scans (2 seconds)
- **Spectral imaging**
 - Ability to make contrast brighter
 - Helps to see subtle leaks

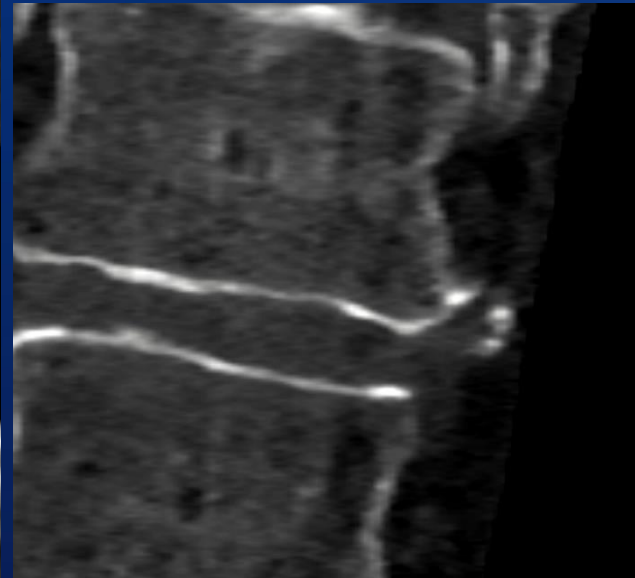
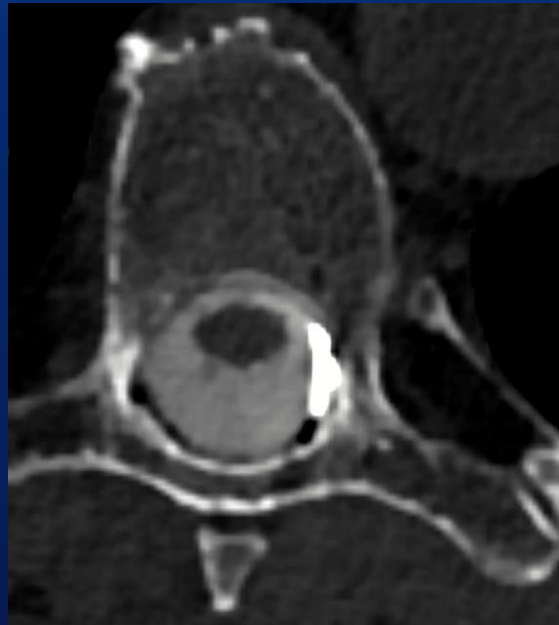




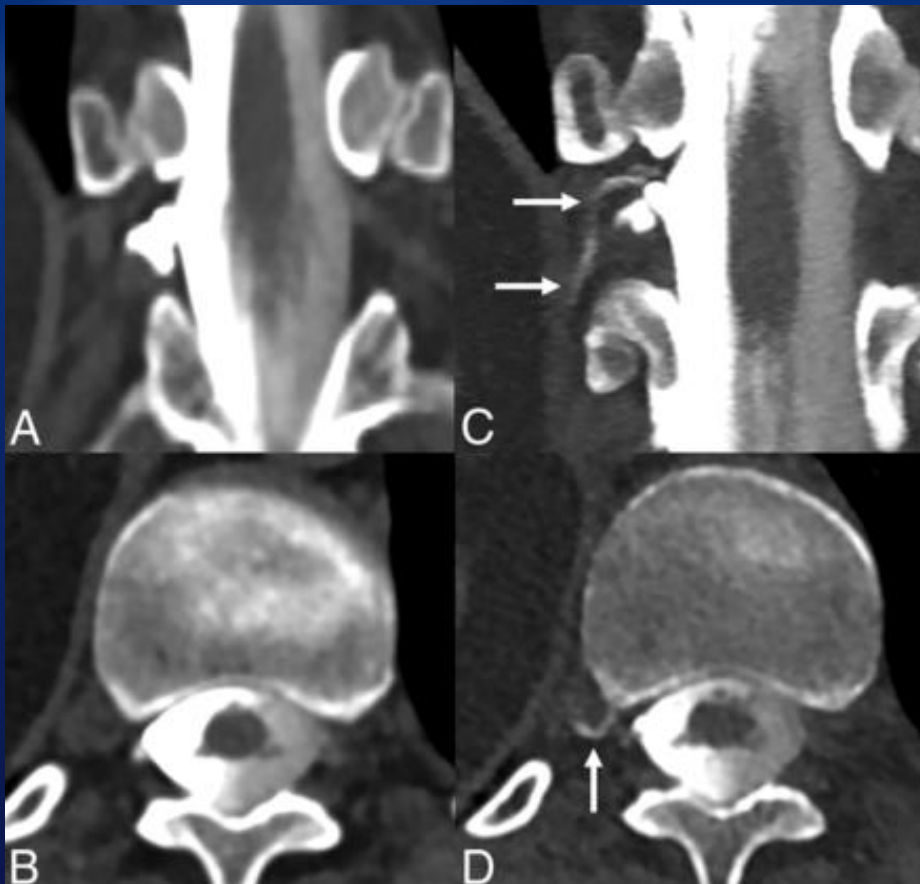
Can photon counting CT find leaks that were missed with other techniques?



Negative DSM



Positive PCD-CTM

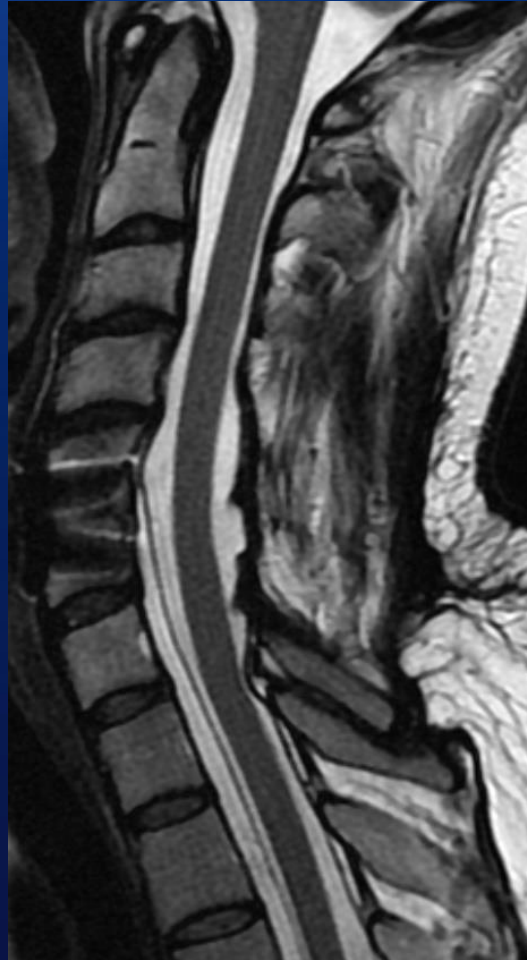

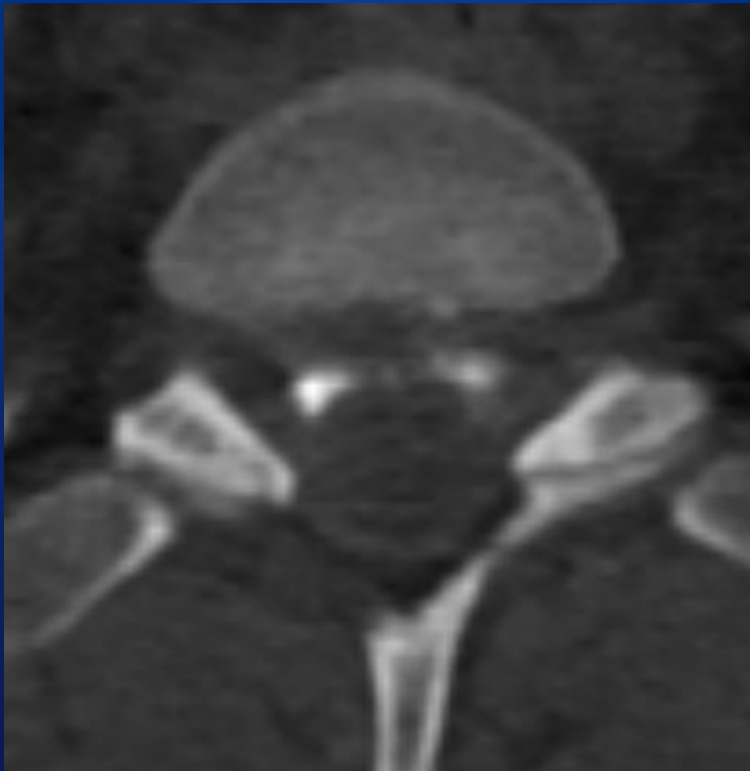
Courtesy of Tim Amrhein, MD,
Duke Health

EID CT

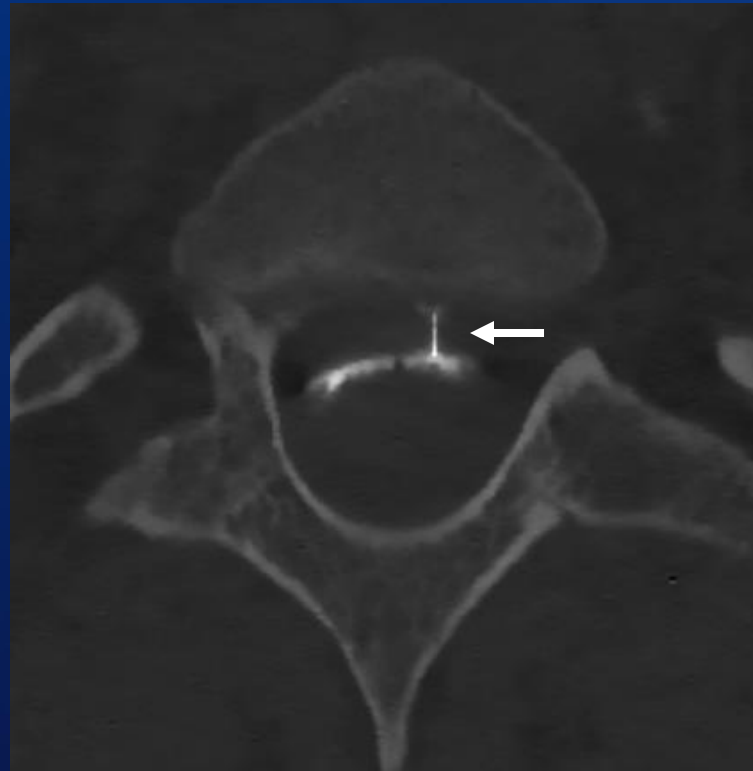
PCD CT

Any use for leaks other than CSF-venous fistulas?

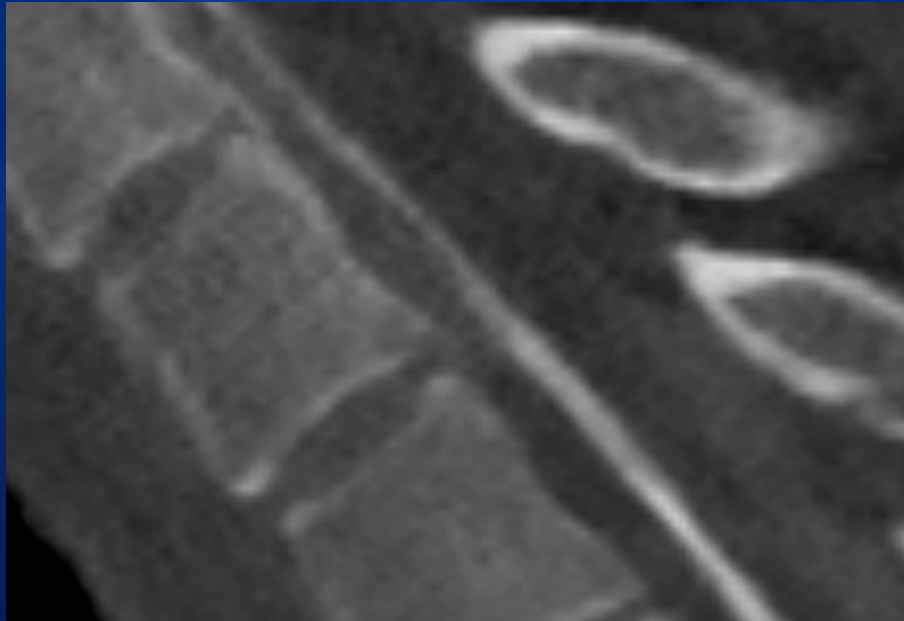




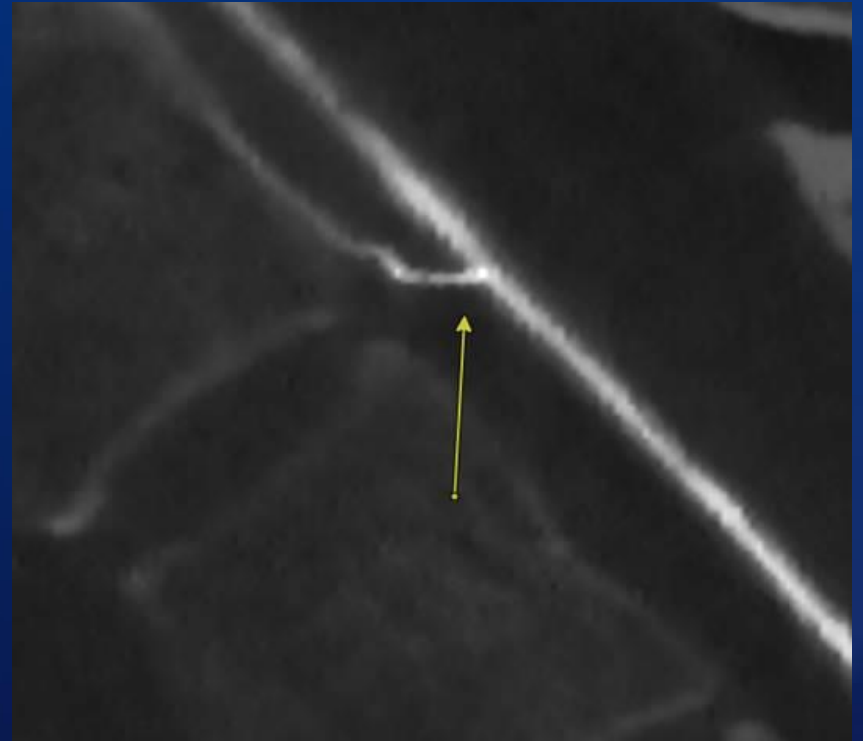
EID CT



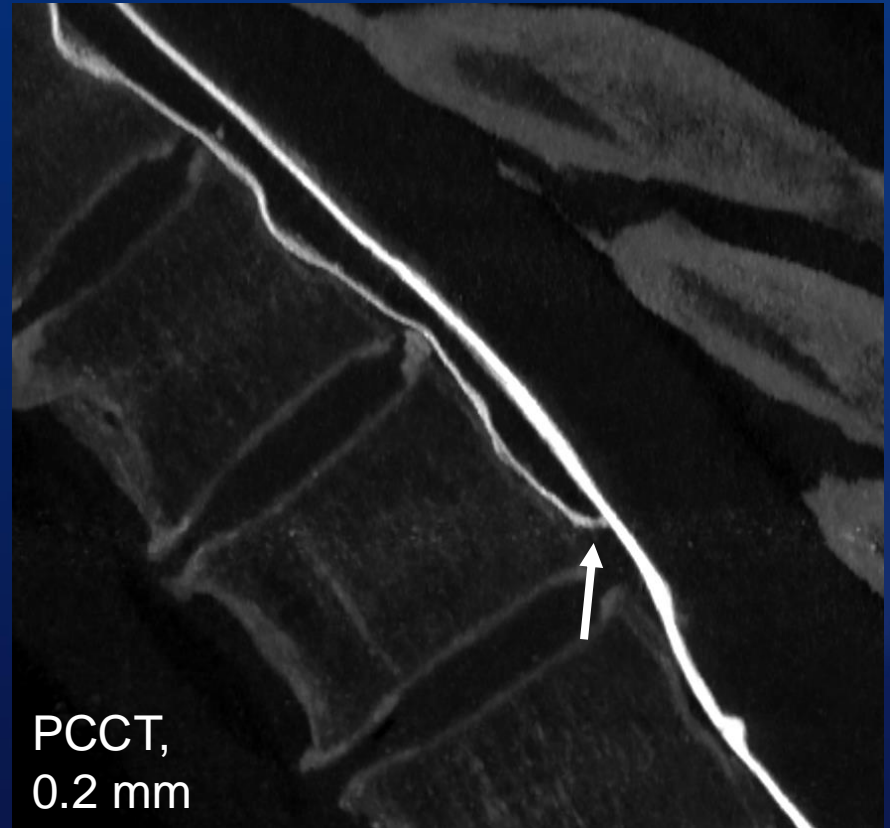
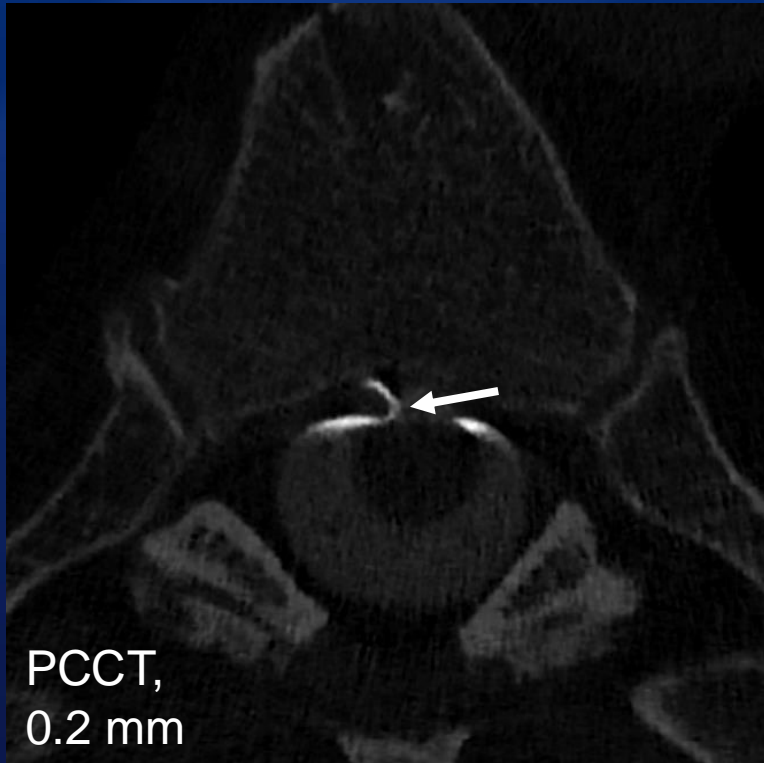
PCCT



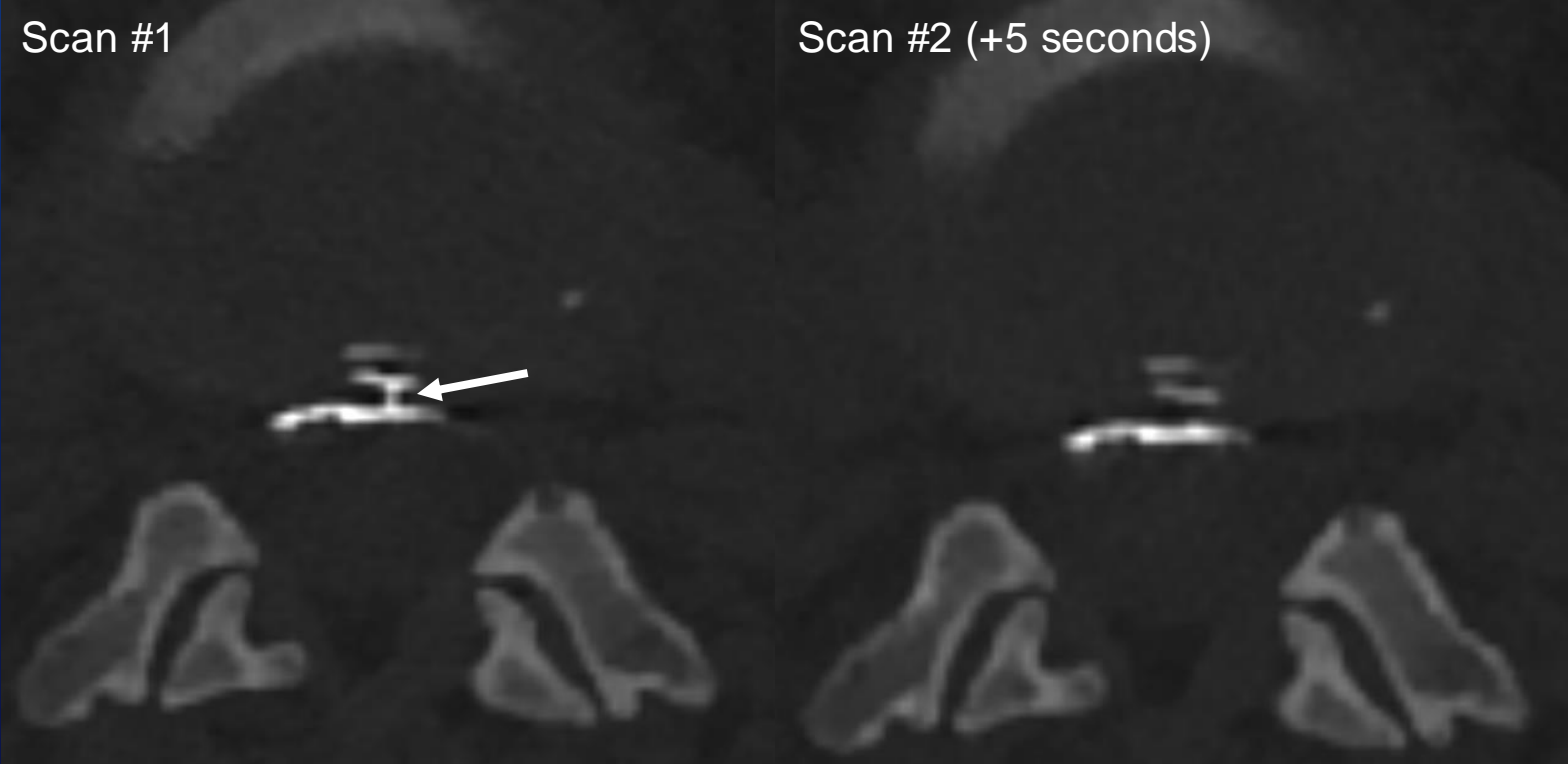
EID CT



PCCT



Benefit of high temporal resolution for dural tears

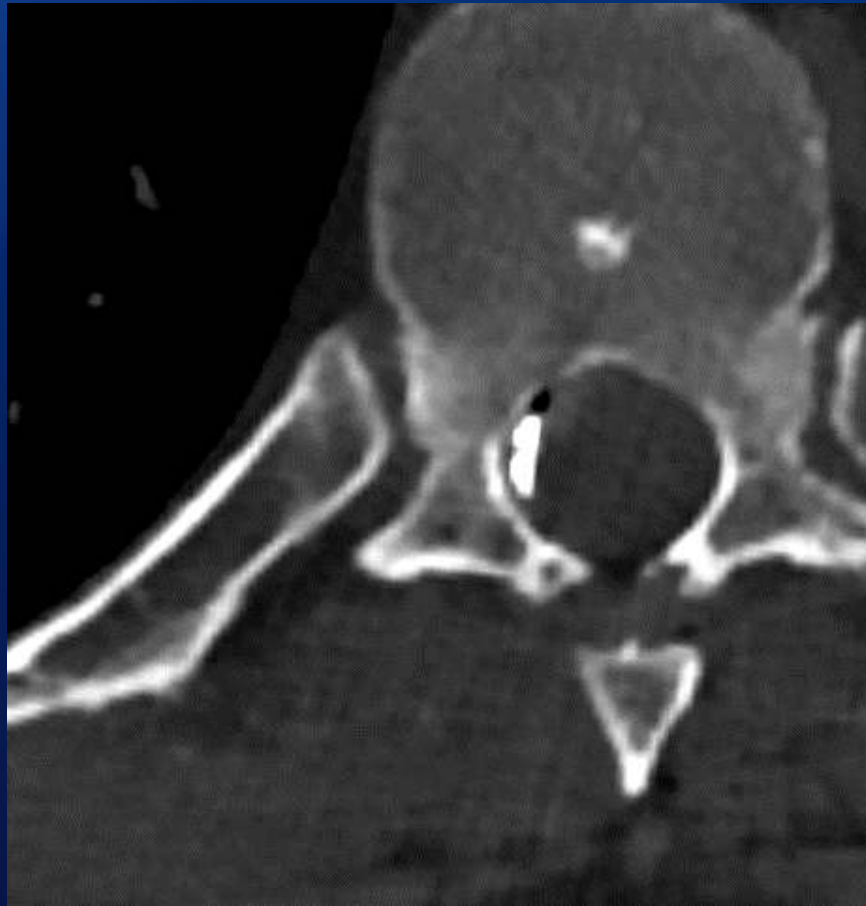


But there's more to it than just imaging...



RIGHT SIDE DOWN

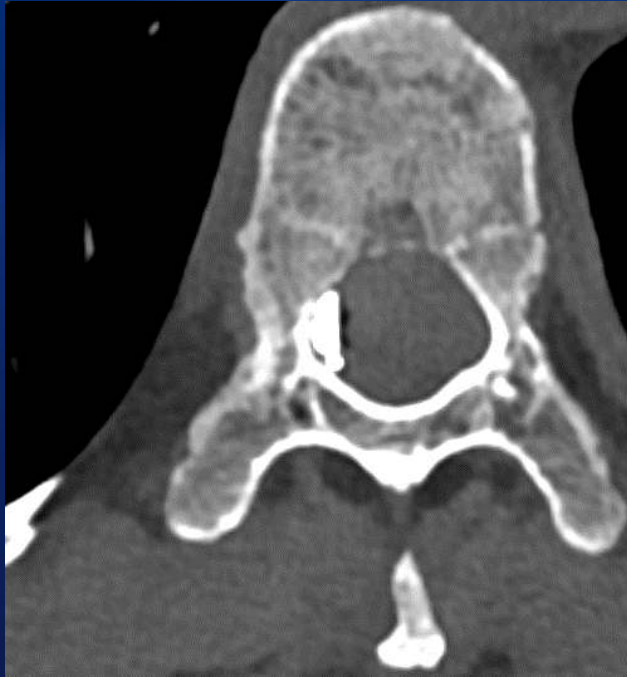DSM



Photon counting CT myelogram

I can't explain why this wasn't visible on DSM

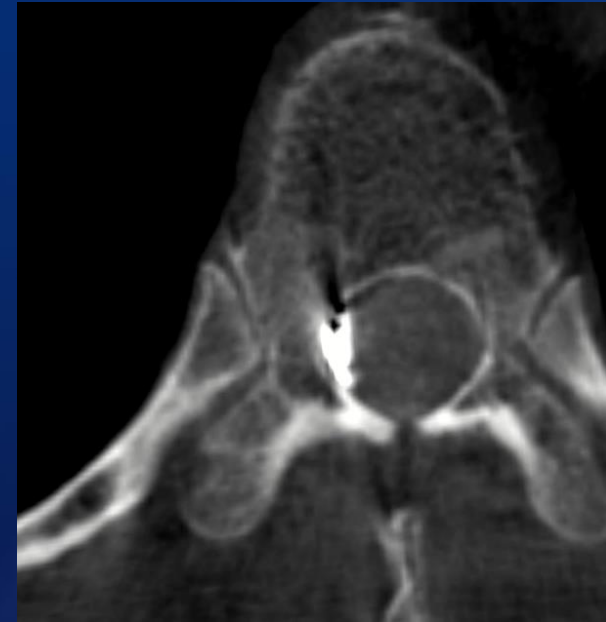
And I can't explain why this one wasn't visible on PCD-CTM...



PCD-CTM



DSM



Cone beam
CTM

Take-home points

- Photon counting CT myelography is very promising for increasing detection of spontaneous CSF leaks, including CSF-venous fistulas and dural tears
- Reasons why? Mainly higher spatial resolution, temporal resolution, and spectral imaging
- However, many factors other than imaging technique matter, and these are often more important than the specific scanner used

Future improvements and active areas of research?

- Faster image reconstruction to facilitate immediate image review
- Prospective studies to prove that photon counting CTM is superior
- Optimization of myelographic technique (timing, # of scans, reconstructions, etc...)

Thanks!

madhavan.ajay@mayo.edu